



ISSN 2682-275X

Alfarama Journal of Basic & Applied Sciences

Faculty of Science Port Said University

July 2021, Volume 2, Issue 2

<https://ajbas.journals.ekb.eg>

ajbas@sci.psu.edu.eg

<http://sci.psu.edu.eg/en/>

DOI: [10.21608/AJBAS.2020.42608.1033](https://doi.org/10.21608/AJBAS.2020.42608.1033)

Submitted: 12 / 09 / 2020

Accepted: 12 / 11 / 2020

Pages: 325-332

Ideal Diuretic Renography Technique For Diagnosis of Upper Urinary Tract Obstruction Focusing on $T_{1/2}$ and T_{max} Physical Parameters

Hoda. Abdelraouf¹, Hossam.M.Gad², Mossad. El-Metwally³

^{1,2} Radiology department, Urology and Nephrology Center, Mansoura University, Egypt.

³ Physics Department, Faculty of Science, Port-Said University, Port-Said, Egypt.

* Corresponding author: hoda_dody2002@yahoo.com

ABSTRACT

Background: Diuresis renography was first used by O'Reilly in 1978 and then by other urologists and radiologists as the method of choice for evaluation the upper urinary tract. Several diuretic renography protocols were classified based on variation in the timing of diuretic administration relative to the radiopharmaceutical which called ($T_{1/2}$). There are three items which Diuresis renography based on: the hydration state of patient, The optimal time to inject the furosemide, The role of the bladder. **Objective:** : Half time ($T_{1/2}$) has an important role to differentiate between obstructed and non-obstructed kidneys by using the stander value of $T_{1/2}$ after performing F-15 min diuretic renography for equivocal cases. **Materials and methods:** This study included 120 renal units (RU) were examined at Urology and Nephrology Center- Mansoura University from 2017 to 2020 by F+10 min diuretic renography protocol. **Results:** Twenty- five (RU) of 120 (RU) revealed as equivocal response after diuretic were done and underwent F-15 min protocol of diuretic renography. Comparing the results of F+10min protocol with F-15 min protocol for the 25 (RU) with equivocal response 19 (RU) were proved to be obstructed by F-15min study with mean \pm SD $T_{1/2}$ values $34.59\text{min}\pm 13.30\text{min}$ which was $14.82\text{min}\pm 2.32\text{min}$ by F+10min ($p=.000$), the mean \pm SD $T_{1/2}$ values of T_{max} was $11.25\text{min}\pm 4.72\text{min}$ by F-15 min which was $6.57\text{min}\pm 4.6\text{min}$ by F+10min ($p=.000$). The other six (RU) were proved to be non-obstructed with mean \pm SD $T_{1/2}$ values $10.10\text{min}\pm 5.42\text{min}$ by F-15 min which was $13.41\text{min}\pm 2.76\text{min}$ by F+10min ($p=0.268$), the mean \pm SD $T_{1/2}$ values of T_{max} was $3.33\text{min}\pm 1.06\text{min}$ by F-15 min which was $5.45\text{min}\pm 3.32\text{min}$ by F+10 min ($p=0.240$). A p value $< .05$ was considered significant. **Conclusion:** Half time ($T_{1/2}$) has an important role to differentiate between obstruction and non-obstruction kidney by using the stander value of $T_{1/2}$ after administrating F-15 min diuretic renography for equivocal cases.

Keywords:

diuresis renography, equivocal, kidney obstruction, furosemide, DTPA.

1. INTRODUCTION

The principle of nuclear medicine studies based on observing the distribution of a pharmaceutical administered to the patient that are swallowed, inhaled, or injected into the body, where they accumulate in the organ or tissue of interest. By introducing a radionuclide in the pharmaceutical, the distribution of this radiopharmaceutical can be measured by observing the amount of radioactivity present. This is accomplished by recording the emissions from the radioactivity, with external radiation detectors (gamma camera) placed in the front of the patients [1].

Diuresis renography was first used by O'Reilly in 1978 and then by other urologists and radiologists as the method of choice for evaluation of the upper urinary tract [2]. He studied the equivocal urinary tract obstruction patient's; he found that using diuretic renogram was preferred to evaluate the equivocal urinary tract obstruction of the patient [3].

Diuresis renal scintigraphy introduced the largest quantitative information about dynamic and functional data. Evaluation of several parameters involves renal uptake, excretion, time to peak activity (T_{max}), and time to half peak ($T_{1/2}$) after washout of furosemide, the obstruction degree can be evaluated. Technetium-99m diethylenetriamine penta-acetic-acid (^{99m}Tc -DTPA) and technetium-99m mercaptoacetyltriglycine (^{99m}Tc -MAG3) are two common radiotracers used to assess the kidney obstruction. [4].

Diuresis renography (DR) used to diagnoses a differentiation renal collecting system dilation, it has the benefit to assess the relative function of the renal, determine the washout of tracer's diuretic-promoted and to provide the possibility for using it to infants with low radiation exposure[5].

Several diuretic renography protocols were classified based on variation in the timing of diuretic administration relative to the radiopharmaceutical which called ($T_{1/2}$) [6].

Obstruction may be measured by assessment the clearance curves, either through a visual assessment of the pattern or the quantitative rate of washout by determining the $T_{1/2}$ (refer to the time talked for the activity in the kidney to decrease to 50 percent of its maximum value). When $T_{1/2} < 10$ min a complete clearance of the ^{99m}Tc -DTPA from the renal pelvis with a normally response and excludes obstruction. When values of $T_{1/2}$ between 10 and 20 min are refers to be equivocal response for diuresis, and a $T_{1/2} > 20$ min is considered as a obstructed kidneys **Fig(1)** [7].

Measurements of $T_{1/2}$ values depend upon choosing of the radiopharmaceutical, the delay between administering the radiopharmaceutical and administering furosemide, the hydration method, the furosemide dose, the volume of the bladder, the interval used to determine the measurement, the presence or absence of a bladder catheter, and the algorithm used to obtain the curve of washout measuring the $T_{1/2}$ [3].

There are three different methods for the injection time of the diuretic furosemide (F):-

1. This method approved by the American Society of Fetal Urology, after the radiopharmaceutical (F + 20 or later), the diuretic is injected at 20 minutes or later, when the entire dilated system is filled with the tracer.
2. The diuretic is injected 15 min before the radiopharmaceutical injection (F-15), this method developed in Europe.
3. In the F – 0 method, the radiopharmaceutical and the diuretic are simultaneously injected this method used by some laboratories in the United States and Australia [8].

The peak time, or T_{max} , refers to the time from radiopharmaceutical injection to the highest renogram curve peak. ^{99m}Tc -MAG3 and ^{99m}Tc -DTPA renograms normally (2.5-5min) and drop to half-peak height after 15 min from injection; however the shape of the whole- kidney renogram curve changes by physiological retention of the tracer in the renal calyces or pelvis[3].

The diuretic should be injected 15 min before the radiopharmaceutical (F-15 diuresis renography), If the maximum possible diuresis is required from the outset, [9].The F+10 protocol leads to equivocal results of 15% to 17% and therefore, the method of the F-15 has been administrated to reduce this rate to 3% [2]. The use of the F-15 method results in a longer study period and bladder over distension that may cause a maximum diuresis of the kidney which reduce the rate of equivocal response. This work aims to determine the ideal time for injecting furosemide in diuretic renography to get accurately diagnosis in the equivocal cases by determining the value of $T_{1/2}$ after administrating two comparative protocols (F+10 min protocol, F-15 min protocol) by using the stander value of $T_{1/2}$ to differentiate between obstructed and non-obstructed cases [2].

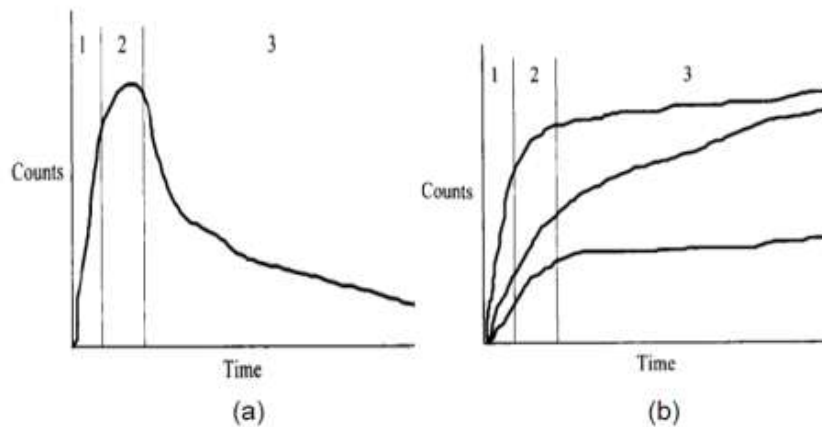


Figure (1): stylized curves of time –activity. A: At normal curve showing the three phases of renogram:1= Phase of perfusion; 2= Phase of cortical transit; 3= Phase of excretion/ clearance. B: At abnormal curves. These curves are typical for obstructive or non-obstructive dilatation with accumulation of tracer in the collecting system.

2. EXPERIMENTAL

2.1 Subjects

Sixty patients with 120 renal units (RU) were prospectively evaluated during 2017-2020 in the Urology and Nephrology Center at Mansoura University with suspected urinary obstruction. All cases administrated by F+10 diuretic renography protocol.

2.2 Apparatus and methods

Renography procedures

- A.** Patient Preparation: The patient was checked about of information, appropriate weight and height and laboratory tests (e.g. Serum Creatinine and urea levels). A 500 ml drink (e.g, water, orange juice) was given 15 minutes before the examination. The patient was asked to void his bladder before the test.
- B.** Patient dosage: The radiopharmaceutical was ^{99m}Tc - DTPA, the dosage of ^{99m}Tc - DTPA adjusted according to body weight, the adult dose at the range 111-259 MBq (3-7 mCi) 0.05 mci /kg. The furosemide dose was 0.5 mg/kg body weight.
- C.** Image preparation and Data acquisition: All patients were examined on Gamma Camera (bright view, Philips medical system company, City: United states of America, software: Jetstream , software of processing unit: EBW). The collimator was low energy general purposes, the photo-peak was selected at 140 keV, the total frames of the study phases are 76 frames during all study (20 min).
- D.** Patient Positioning: The patients were placed in supine position before injection. Before the injection the field of view was verified with a marker, both kidneys, ureters and bladder were included.

The two protocols of F+10 min and F-15min diuretic renography were performed as follows:

F + 10 Diuretic Renography protocol

The patient at the state of good hydration (500ml water) before the study. The dose of ^{99m}Tc DTPA was injected intravenously in the patient as being a bolus and then, the computer system was acquired data in frame mode. At ten (10) min, a furosemide dose of 0.5 mg/kg body weight was injected. the total time of acquisition was 20 min.

F -15 Diuretic Renography protocol

After 2 days the same patient which had equivocal result for diuresis, the patient had a good condition of hydration and that there are no clinical reasons for diuresis. The patient was Injected furosemide at a dose 0.5 mg/kg body weight before 15 min of the study. The radiopharmaceutical was injected as a routine renogram and was continued until 20 min. The total time of acquisition is 35 minutes.

2.3 Statistical analysis

The result of the curve pattern, drainage half time ($T_{1/2}$), split renal function (%) and The time to peak (T_{max}) in the two protocols (F+10, F-15) were recorded and compared by the paired t test using the SPSS software (Statistical package for the social sciences, version 20). *P < 0.05 was considered statistically significant.*

3. RESULTS

This study included 60 patient with 120 renal units (RU). This patients were examined by the F+10min diuretic renography protocol, 42 (RU) had mean $T_{1/2}$ value more than 20min and diagnosed as obstructed kidneys (Fig 2) and the other 53 (RU) had mean $T_{1/2}$ value less than 10min and diagnosed as non-obstructed, well-functioning kidneys (Fig 3). The remaining 25 (RU) had mean $T_{1/2}$ value between 10min to 20min with equivocal results for diuresis (Fig 4), the mean (\pm SD) of $T_{1/2}$, Split Function and T_{max} illustrated at (Table 1).

Table 1: The mean \pm SD of $T_{1/2}$, Split Function and T_{max} of all renal units by F+10 min protocol

RU	No. of RU	$T_{1/2}$ (Mean \pm SD) min	Split Function (Mean \pm SD)%	T_{max} (Mean \pm SD)%
Obstruction	42	36.51 \pm 10.80	31.44 \pm 12.20	11.08 \pm 4.29
Non-obstructed	53	8.07 \pm 1.93	67.35 \pm 10.57	3.61 \pm 1.51
Equivocal	25(21%)	14.45 \pm 2.47	44.29 \pm 14.39	6.30 \pm 4.31

After administrating F-15 min protocol for (25RU) equivocal cases, the overall results indicated that obstruction was found in 60 (RU) out of 120 (RU) and 60 (RU) out of 120 (RU) were non-obstructed, the mean (\pm SD) of $T_{1/2}$, Split Function, T_{max} for all obstructed renal units and non-obstructed renal units illustrated at (Table 2).

Table 2: The mean \pm SD of $T_{1/2}$, Split Function and T_{max} of total obstructed renal units and non-obstructed renal units after performing F-15min protocol for equivocal cases.

RU	No. of RU	$T_{1/2}$ (Mean \pm SD)min	Split Function (Mean \pm SD)%	T_{max} (Mean \pm SD)%
Total Obstruction	60	35.9618 \pm 11.59272	32.9903 \pm 11.94969	11.1818 \pm 4.37166
Total Non-obstructed	60	8.4527 \pm 2.29530	66.2168 \pm 10.91621	3.4998 \pm 1.45419

Comparing the results of F+10min protocol with F-15 min protocol for the 25 (RU) with equivocal response 19 (RU) were confirmed as obstructed Fig(5), The other six (RU) were confirmed as non-obstructed by F-15 min protocol Fig(6). The comparison between the mean \pm SD of $T_{1/2}$, Split Function and T_{max} of the (25)RU by performing F+10 min protocol and F-15 min protocol illustrated at (Table 3), *A p value less than .05 was considered significant.*

4. DISCUSSION

Some radiologists explain the study by visually analyzing the washout curves such as cases of obstructed kidney and non-obstructed kidney, but some prefer analyzing the washout curves time for $T_{1/2}$ (the activity in the collecting system to fall to 50% of its original value of the radiopharmaceutical), The time to peak or (T_{max}) 99mTc-MAG3 and 99mTc-DTPA renograms normally peak (2.5-5 min).

Normal $T_{1/2}$ values depend upon the radiopharmaceutical, the delay between administering the radiopharmaceutical and administering furosemide, the method of hydration, the dose of furosemide, and the interval used to make the measurement. Prompt clearance of the radiopharmaceutical from the renal pelvis with a

$T_{1/2}$ of less than 10 min is a normal response, values between 10 and 20 min are considered equivocal results, and a $T_{1/2}$ greater than 20 min suggests obstruction.

Table 3: shows the comparison between the mean \pm SD of $T_{1/2}$, Split Function and T_{max} of equivocal renal units by performing F+10 min protocol and F-15 min protocol

25 Equivocal Renal Units						
F+10 min protocol				F-15 min protocol		
	$T_{1/2}$ (Mean \pm SD) min	T_{max} (Mean \pm SD) min	Split Function (Mean \pm SD) %	$T_{1/2}$ (Mean \pm SD) min	T_{max} (Mean \pm SD) min	Split Function (Mean \pm SD) %
19 RU (Obstructed)	14.82 \pm 2.32 P=.000	6.57 \pm 4.6 P=.000	41.05 \pm 14.59 P=0.031	34.59 \pm 13.30	11.25 \pm 4.72	39.88 \pm 14.23
6 RU (Non-Obstructed)	13.41 \pm 2.76 P=0.268	5.45 \pm 3.32 P=0.240	54.56 \pm 7.88 P=0.463	10.10 \pm 5.42	3.33 \pm 1.06	55.25 \pm 9.50

In F-15 renography, the kidney takes enough time to deal with the furosemide to reach the maximum effect. This method helps in differentiating between kidney obstruction and non-obstruction.

In our study 25 (RU) with equivocal result in the F+10 protocol, 19 (RU) had an obstructive pattern in the F-15 with half time or $T_{1/2}$ equal 34.59 min and had the value of F+10min protocol equal 14.82min ($p=0.000$) which mean there is an increase in $T_{1/2}$ when the diagnosis is obstructed pattern $T_{1/2} > 20$ so, there is a significant change in the value of $T_{1/2}$ after F-15min protocol; the value of T_{max} equal 11.25min by F-15 min protocol and T_{max} equal 6.57min by F+10 min protocol ($p=0.000$); this mean that there is an increase in T_{max} value at obstructive kidneys after administrating F-15 min protocol where n the value of T_{max} of normally renogram at the range (2.5-5 min). The other 6 (RU) with equivocal pattern in the F+10 protocol which proved to be non-obstructed, the value of $T_{1/2}$ equal 13.41 min, after F-15 the value of $T_{1/2}$ equal 10.10min ($p=0.268$), this mean that there is a decrease in $T_{1/2}$ by administrating F-15 min protocol when the diagnosis is non- obstructed pattern $T_{1/2} < 10$; the value of T_{max} equal 3.33min by F-15 min protocol and T_{max} equal 5.45min by F+10 min protocol ($p=0.240$); this mean that there is a decrease in T_{max} value at non-obstructive kidneys after administrating F-15 min protocol.

In equivocal cases, some recommend repeating the study with the “F minus 15 renogram” the furosemide is then given at 15 min before the radiopharmaceutical, so the patient will be in a good state of maximum diuresis at the time when the radiopharmaceutical is administered.

Kumar and Hanuwant studied 51 adult patients of primary hydronephrosis. Both F+20 and F-15 diuretic Technetium-99m diethylenetriaminepentacetate ($^{99m}\text{Tc-DTPA}$) renography protocol were administrated for all patients. They are found that A total 60 RU with HDN (42 patients with unilateral and 9 patients with bilateral HDN) were included in this study. The equivocal results were significantly lower in F-15 protocol (1/60) than F+20 protocol (24/60), So the widely practiced F+20 protocol has very high incidence of inconclusive results ranging from 10 to 40% [7].

Similarly, in our study 25 (RU) 21% were equivocal in F+10 protocol. The F-15 protocol conclusively categorized 6 (RU) as nonobstructed, 19 (RU) as a obstructed, so there are a clear reduction in the number of equivocal cases and this mean that F-15 min protocol is the gold stander method for differentiation between obstruction and non-obstruction cases.

Babu and Venkatsubramaniam; studied on 148 diuretic renograms in infants and children to evaluate unilateral Grade 3–4 HDN. The number of interrupted studies was significantly less in F+0 compared with F-15 and F+20. The F+0 and F-15 protocols are superior to the F+20 protocol in reducing the number of equivocal curves [10]. Similarly in our study the number of equivocal response reduced by using F-15 min protocol.

Taghavi and Ariana; studied on 21 patient with pyelocaliceal system dilatation used F+20 and F-15 methods for differentiation of upper urinary tract dilatation from obstruction. The F+20 and F-15 protocol diuresis renography were administered for all patients . The overall results indicated that 16 out of 21 patients (76.2%) were obstructed by the F-15 protocol, while 11 (52.4%) were obstructed by the F+20 protocol ($P= 0.01$) [2].

In our study the patients underwent diuresis renography using the F+10 and F-15 protocol. The overall results , obstruction was found in 60 (50%) by the F-15 protocol, while it was found in 42(35%) by F+10 protocol ($P=0.000$).

Foda et al [11]. studied on a 72 children were randomly assigned to 1 of 2 standardized diuresis renography protocols. On the investigated side, the F-15 scan showed seven times more obstruction than the F+20 scan, and that difference was statistically significant.

In our study there was a statistical significant of the drainage time ($T_{1/2}$) between F+10 min protocol and F-15 min protocol, the latter is longer and ($P=0.000$).

Limitations of the study refers to the role of the physical parameter ($T_{1/2}$), split function but I didn't studied the parameter of GFR because there is no differentiate in the value of GFR after administrating F-15 min protocol. The value between the mean and the standard deviation was long because the number of patient which examined was low.

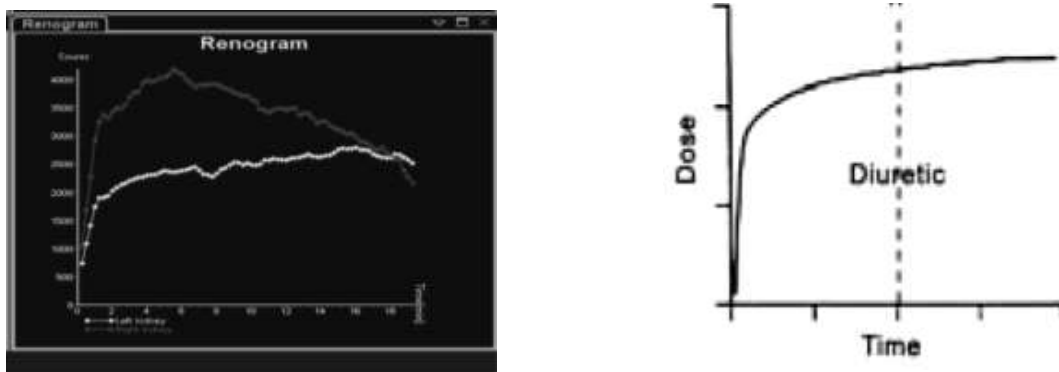


Figure (2): A patient with suspected urinary obstruction underwent F+10min the renogram curve indicated that there is an obstruction in the left kidney, Non obstructed right kidney.

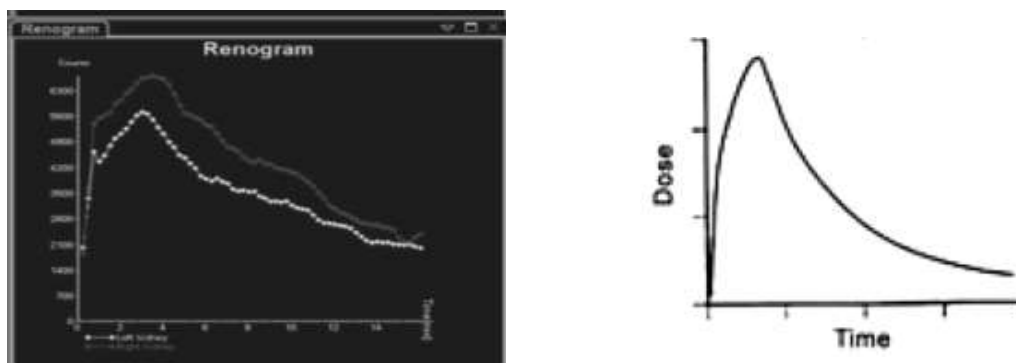


Figure (3): A patient with suspected urinary obstruction underwent F+10min the renogram curve indicated that there is no obstruction in both kidneys.

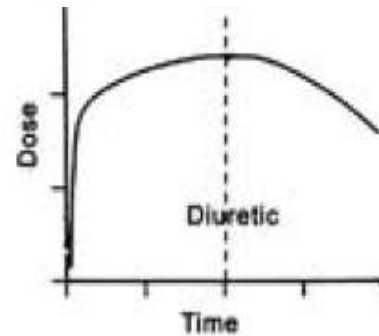
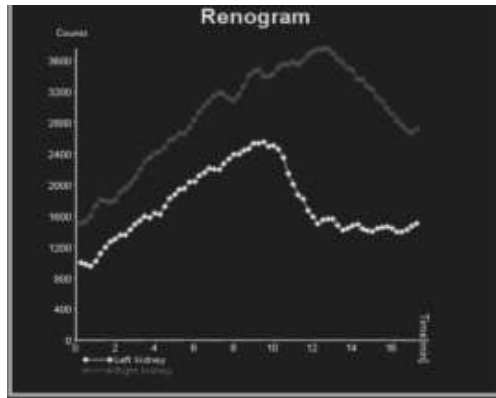


Figure (4): A patient with suspected urinary obstruction underwent F+10min the renogram curve indicated that there is an equivocal response to diuresis at the left kidney. F-15 min is recommended for further assessment of the left kidney, Well function non obstructed right kidney.

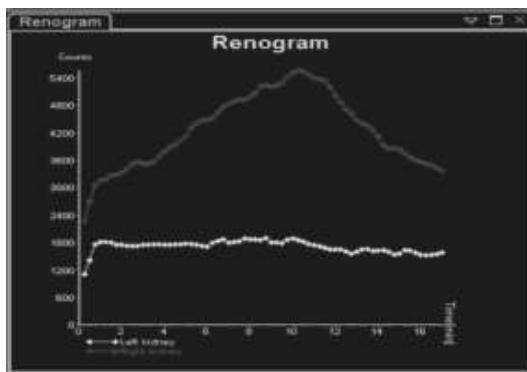


Figure (5): In the same patient after time by applying F-15 min protocol, furosemide was injected I.V 15 minutes before injection of Tc-99m DTPA. The left kidney showed reduced perfusion & tracer uptake and delayed excretion without improvement in response to diuresis (obstructed kidney).

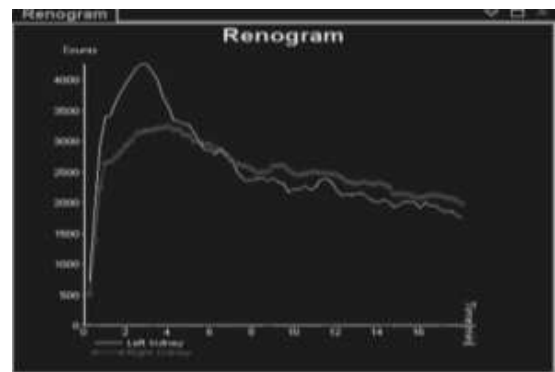


Figure (6): A patient with non-obstructive right kidney which underwent to F-15 min protocol. The renogram curve indicated that the right kidney is non-obstructed after F-15 min protocol administration.

5. CONCLUSION

Half time ($T_{1/2}$) has an important role to differentiate between obstructed and non-obstructed kidneys by using the standard value of $T_{1/2}$ after performing F-15 min diuretic renography for equivocal cases. In our study, F-15 diuresis renogram protocol was associated with significantly less equivocal results than F+10 protocol. Moreover, F-15 protocol allowed explanation the cases of equivocal results of F+10 protocol.

Therefore, F-15 diuretic renogram protocol is the gold standard and sensitive radiological method for diagnosis of urinary obstruction with which $T_{1/2}$ time is calculated correctly to be adjuvant physical parameter for confirming diagnosis.

REFERENCES

- [1] Saha, Gopal B. Radiation biology. Physics and Radiobiology of Nuclear Medicine., Springer, New York, NY., (2006): 226-267.
- [2] Taghavi, R., Ariana, K. and Arab, D. Diuresis renography for differentiation of upper urinary tract dilatation from obstruction: F+ 20 and F-15 methods. Urology journal., 4.1(2009): 36-40.
- [3] Taylor, Andrew T. Radionuclides in nephrourology, part 1: radiopharmaceuticals, quality control, and quantitative indices. Journal of Nuclear Medicine., 55.4 (2014): 608-615.
- [4] Joseph, David B. Ureterovesical Junction Anomalies: Megaureters. Pediatric Urology. WB Saunders., (2010): 272-282.
- [5] Tartaglione, G., Townsend, D. M., Bassi, P. F., Bolton, R. C. D., Giammarile, F. and Rubello, D. Diuresis renography in equivocal urinary tract obstruction. A historical perspective., Biomedicine & Pharmacotherapy., 116 (2019): 108981.
- [6] Alkhalwaldeh, K., Khraisat, S., Hazza, I. Dual time 99MTC-MAG3 diuretic renography and new criteria in the assessment of obstructive uropathy. JRMS., 16.3(2009): 47-54.
- [7] Kumar, M. T. and Hanuwant, S. Comparison of the F+ 20 and F-15 diuresis technetium-99m diethylenetriaminepentacetate renography protocols for diagnosis of ureteropelvic junction obstruction in adult patients with hydronephrosis. Indian journal of nuclear medicine., IJNM: the official journal of the Society of Nuclear Medicine., India., 33.1(2018), 39.
- [8] Shulkin, B.L., Mandell, G.A., Cooper, J.A., Leonard, J.C., Majd, M., Parisi, M.T., Sfakianakis, G.N., Balon, H.R. and Donohoe, K.J. Procedure guideline for diuretic renography in children 3.0. Journal of nuclear medicine technology., 36.3(2008): 162-168.
- [9] Prigent, A. and A. Piepsz. Functional imaging in nephro-urology., CRC Press: (2006).
- [10] Babu, R., Venkatsubramaniam, D.; Venkatachalapathy, E. "F+ 0 diuretic protocol is superior to F-15 and F+ 20 for nuclear renogram in children." Indian journal of urology: IJU: journal of the Urological Society of India.; 31.3 (2015): 245.
- [11] Foda, M. M. R.; Gatfield, C. T.; Matzinger, M.; Briggs, V.; Wells, G.; Walker, S.; Schillinger, J. F. "A prospective randomized trial comparing 2 diuresis renography techniques for evaluation of suspected upper urinary tract obstruction in children." The Journal of urology., 159.5(1998): 1691-1693.